

DIAGNOSIS OF DIABETIC RETINOPATHY AT AN EARLY STAGE THROUGH RETINAL VESSEL SEGMENTATION

¹ MERLIN JABA MALA C,

² Mr.M.SUDHAKAR M.E

² Assistant Professor

¹ Department of Computer Science and Engineering, ² Department of Computer Science and Engineering
Varuvan Vadivelan Institute of Technology, Tamil Nadu

ABSTRACT

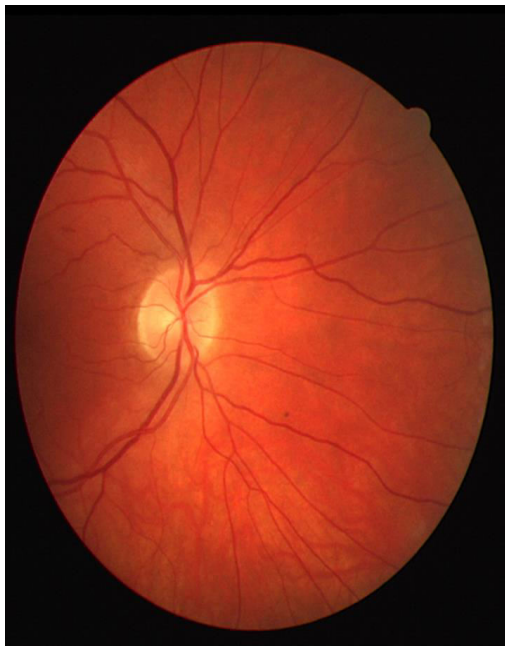
Diabetic retinopathy is the most common diabetic eye disease and a leading cause of blindness in the world. Diagnosis of diabetic retinopathy at an early stage can be done through the segmentation of blood vessels of the retina. In this work, the performance of descriptive statistical features in retinal vessel segmentation is evaluated by using fuzzy logic, an artificial neural network classifier (ANN), a support vector machine (SVM), and classifier fusion. Newly constructed eight features are formed by statistical moments. Mean and median measurements of image pixels' intensity values in four directions, horizontal, vertical, up-diagonal, and down-diagonal, are calculated. Features, F1, F2, F3, and F4 are calculated as the mean values and F5, F6, F7, and F8 are calculated as the median values of a processed pixel in each direction. A fuzzy rule-based classifier, an ANN, a SVM, and a classifier fusion are designed. The publicly available DRIVE and STARE

databases are used for evaluation. The fuzzy classifier achieved 93.82% of an overall accuracy, 72.28% of sensitivity, and 97.04% of specificity. For the ANN classifier, 94.2% of overall accuracy, 67.7% of sensitivity, and 98.1% of specificity are achieved on the DRIVE database. For the STARE database, the fuzzy classifier achieved 92.4% of overall accuracy, 75% of sensitivity, and 94.3% of specificity. The ANN classifier achieved the overall accuracy, sensitivity, and specificity as 94.2%, 56.9%, and 98.4%, respectively. Although the overall accuracy of the SVM is calculated lower than the fuzzy and the ANN classifiers, it achieved higher sensitivity rates. Designed classifier fusion achieved the best performance among all by using the proposed statistical features.

INTRODUCTION

The optic disc (OD) is one of the most important retinal landmarks to be detected. In normal conditions, it appears as a relatively circular yellowish disk, brighter

than its surroundings. It is also the region where the retinal veins and arteries emerge and spread, covering the retina. Significant changes in the shape, color, and depth provide quantitative metrics information for the detection of pathologies associated with the OD, e.g., glaucoma, revascularization on the disk, and papilledema. Moreover, the automatic localization of the OD provides an invaluable help in the screening of diabetic retinopathy and macular degeneration, by discarding the OD as a potential confounder, relative to retinal exudates and other bright lesions.



In addition, the OD provides a reference point to the detection of other important retinal landmarks like the fovea and retinal vasculature. Although the OD main features and characteristics are relatively easy to

describe, its automatic localization can be a difficult task. Furthermore, this localization is particularly difficult in pathological retinas or in cases where the OD exhibits an altered appearance. Many methods have been proposed to detect the OD. They can be divided in two main approaches: Appearance-based methods and model based methods.

Appearance-based methods rely on shape characteristics and on the fact that the OD is usually the brightest region in normal retinal images. Although these methods exhibit a good performance in normal retinal images, they often fail when in the presence of pathological signs, the existence of confusing elements and poor quality images. Model-based methods make use of the vasculature information and of the fact that the vessels emerge from the OD. This approach tends to be the most effective and reliable, even in the presence of retinal diseases. Most relevant examples of this approach are the geometrical model proposed by Foracchia et al., where the retinal vessels are modeled as two parabolas, with the vertex located in the OD position. Fuzzy convergence is a voting-type algorithm developed by Hoover et al., where the originating

vessel map convergence point near the OD center is determined. Kandeet et al. proposed to identify the region with most vessels branches and, thus, the OD localization. Youssif et al. and Frank ter Haar proposed to fit the vasculature orientations on a directional model, being the OD located in the point where the maximum matching is achieved.

Tobin et al. segmented the retinal vasculature and considered several OD and vessel properties. Subsequently, a two-class Bayesian classifier and some prior knowledge is used to predict the OD localization. Although most of these methods result in effective OD localization, they tend to require large computation time, becoming impractical for clinical use. Hence, recent effort has been made for the development of simultaneously fast and reliable methods. Mahfouz et al. developed a technique where two projections of certain image features that encode the x and y coordinate of the OD are obtained. The resulting 1-D projections are then searched to determine the localization of the OD.

EXISTING SYSTEM:

In this paper, the fitness of estimating vessel profiles with Gaussian function is evaluated and an amplitude-

modified second-order Gaussian filter is proposed for the detection and measurement of vessels. Mathematical analysis is given and supported by a simulation and experiments to demonstrate that the vessel width can be measured in linear relationship with the “spreading factor” of the matched filter when the magnitude coefficient of the filter is suitably assigned. The absolute value of vessel diameter can be determined simply by using a recalibrated line, which is typically required since images are always system dependent. The experiment shows that the inclusion of the width measurement in the detection process can improve the performance of matched filter and result in a significant increase in success rate of detection.

Ocular fundus image can provide information on pathological changes caused by some eye diseases and early signs of certain systemic diseases, such as diabetes and hypertension. Analyzing and interpreting fundus images have become a necessary and important diagnostic procedure in ophthalmology and a considerable research effort has been devoted to automate this process. The structure of retinal vessels is a prominent feature that reveals further information on the state of diseases that are reflected in the form of measurable abnormalities in

diameter, color, and tortuosity. Thus, reliable methods of vessel detection that preserve various vessel measurements are needed.

DRAWBACKS:

- It only takes into account information local to each pixel through image filters, ignoring useful information from shapes and structures present in the image.
- This method did not perform well for very large variations in lighting throughout an image, but this occurred for only one image out of the 40 tested from both databases.
- It is possible to use only the skeleton of the segmentations for the extraction of shape.
- The main disadvantage of morphological methods is that they do not consider the known vessel cross-sectional shape information, and the use of an overly long structuring element may cause difficulty in detecting highly tortuous vessels

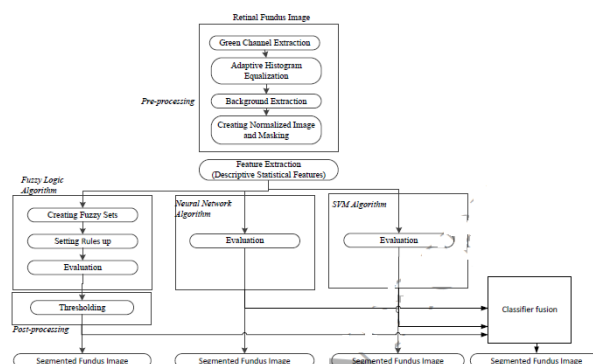
PROPOSED SYSTEM

METHODOLOGY

The schema of the proposed model, given in Fig.1, includes four main stages which are (1) pre-processing that includes

green channel extraction, adaptive histogram equalization (AHE), background extraction, and masking; (2) feature extraction; (3) classification (fuzzy logic algorithm that has creating fuzzy sets, rule list classifier fusion); and (4) post-processing, which is thresholding and removing residual.

BLOCK DIAGRAM



PRE-PROCESSING

Retinal fundus images may have poor contrast and noisy backgrounds. Hence, the images need to be enhanced before any segmentation method. Here, the preprocessing stage performs green channel extraction and adaptive histogram equalization (AHE) to enhance the contrast level of the image by uniformly spreading the image intensity levels. Fig. 2(a) shows an original retinal fundus image that has red-green-blue (RGB) channels. The green channel of retinal images provides more details about the vessel structure. The red and blue channels do not provide as clear

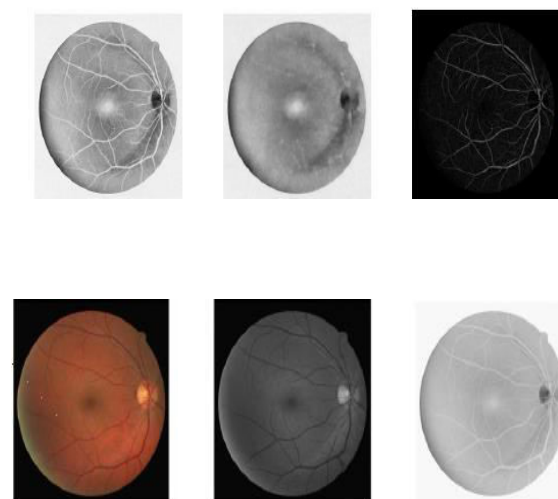
images of blood vessels as the green channel and this is due to low contrast and poor dynamic range. AHE (Pizer et al., 1987) is applied to the complement of the green channel image (Fig.2 (c)) in order to enhance the contrast. The enhancement takes shape for each of these areas individually when the AHE processes on small areas instead of the entire image (Hossain & Alsharif, 2007). Fig.3 (a) shows the image after AHE was applied. Morphological operations are used to create a uniform background image (Hameed et al., 2015). As it can be seen in Fig.3 (b), the background became non-uniform after the AHE stage while the vessel structure got a better contrast. The most basic morphological operations are erosion and dilation. Erosion trims pixels on object boundaries, while dilation adds pixels to the boundaries of objects in the digital images. The number of pixels trimmed from or added to objects in the image depends on a structuring element. The structuring element is known as a matrix with values 1 and 0 only, and takes different shapes and sizes with respect to the application

The dilation of the erosion is called opening morphology that is defined by Eq.1.

$$() (1)$$

where, refers to the morphological opening process of image A with a structuring

element B, and and refer to erosion and dilation, respectively. In order to generate a background image, IBK, the blood vessels are suppressed by an opening morphological operation with a non-flat and ball-shaped structuring element. Its radius in the X-Y plane is 6 and its height is 6. This background is subtracted from the result of the adaptive histogram equalization, IAHE, so as to obtain a normalized image, INR. $(i, j) = (i, j) - (i, j) + (2)$ where i and j are pixel coordinates. The normalized image is generated by Eq.2. Masking is applied to remove residual outside the fundus region of interest (ROI) in the entire normalized image. The background and normalized image can be seen in Fig. 3 (b) and (c), respectively.



A Original retinal fundus image, (b) Green channel image, (c) Complement of the green channel image.

FEATURE EXTRACTION

In this study, means and medians of the pixels' intensity values are calculated in four directions: horizontal, vertical, up diagonal, and down diagonal as features. Numerical summary measurements for a given data set might convey some of its significant features and help to characterize the data set. One important characteristic of a set of numbers is its center. The most known measure of the center is the mean of the set. The value of sample mean is in a sense more precise than the accuracy associated with any single observation. For this reason, the mean is used as one of the features in the set. Fig.4 demonstrates the calculation of these features. The processed pixel is represented in red and its neighbors are represented in yellow. Features, F1, F2, F3, and F4 are calculated as the mean values in Eqs.4-7. The sample median is defined as the middle value when the observations are ordered from smallest to largest in magnitude. In contrast to the mean, the sample median is insensitive to a number of small or large sample values. When the data set distribution is normal, the sample mean is a better descriptive statistical feature to use. However, retinal blood vessel structure is unique for everyone. The data set, intensity values of the processed pixels, in four directions may or may not

have a normal distribution. There is no guarantee that the intensity values of the processed pixels will normally distributed. If the distribution is skewed, the sample median will be a better description of the data set.

CLASSIFIER DESIGN

F UZZY LOGIC ALGORITHM

The theory of fuzzy sets was introduced by Lotfi A. Zadeh in 1965 (Zadeh, 1965). A fuzzy set is a class of objects. The sets are characterized by a membership function that assigns a degree of membership between zero and one to each object. By means of this characteristic, fuzzy logic techniques give more satisfactory results than conventional mathematical models for complex and uncertain systems. In recent years, the use of fuzzy logic technique has been a very popular method in many areas such as control systems, robotics and noise recognition algorithms [Uzkent, Barkana, & Yang, 2011). It is also successful in the area of image processing (Kerre & Nachtegaele, 2000). There are four principal elements for a fuzzy system: fuzzifier, fuzzy rule base, fuzzy inference engine, and defuzzifier (Wang & Mendel, 1992). Basic configuration of fuzzy systems is shown in Fig.6. The fuzzifier performs a mapping from the crisp input to fuzzy set. The input is characterized by a membership function. The fuzzy rule base

consists of a set of linguistic rules in the form of “IF a set of conditions are satisfied, THEN a set of consequences are inferred.” The fuzzy inference engine is decision-making logic that employs fuzzy rules from the fuzzy rule bases to determine a mapping from the fuzzy sets in the input space to the fuzzy set in the output space (Russo & Jain, 2000). The defuzzifier performs a mapping from the fuzzy set in the output to crisp output.

CONCLUSION

Computer-aided retinal blood vessel classification is important for early diabetic retinopathy detection, glaucoma, and age-related macular degeneration which are known as the most prevalent causes of blindness in the world. This study proposed newly constructed descriptive statistical features to segment retinal vessel structure. The features are formed by means and medians of the image pixels' intensity values in four directions: horizontal, vertical, up diagonal, and down diagonal. The performance evaluation of the features is performed by a rule-based fuzzy classifier and a classifier fusion. Our experimental results show that all classifiers achieved compatible classification accuracies with sensitivity and specificity values

REFERENCES

1. Abramoff, M. D., Garvin, M. K., & Sonka, M. (2010). Retinal imaging and image analysis. *IEEE Transactions on Medical Imaging*, 3, 169-208.
2. Bressler, N. M., Bressler, S. B., & Fine, S. L. (1988). Age-related macular degeneration. *Survey of Ophthalmology*, 32(6), 375-413.
3. Can, A., Shen, H., Turner, J. N., Tanenbaum, H. L., & Roysam, B., (1999). Rapid automated tracing and feature extraction from retinal fundus images using direct exploratory algorithms. *IEEE Transactions on Information Technology in Biomedicine*. 3(2), 125–138.
4. Chaudhuri, S., Chatterjee, S., Katz, N., Nelson, M., & Goldbaum, M. (1989). Detection of blood vessels in retinal images using twodimensional matched filters. *IEEE Transactions on Medical Imaging*, 8(3), 263–269.